

Use of Artificial Intelligence based Image Analysis and Decision Support System (iADSS) for classification of Wistar rat histopathology images into Normal and Not-Normal for organs of immune system.



Rajesh Ugalmugle¹; Madhav Marathe²; Chanukya Chama¹; Anindya Hajra¹

¹ Aditya Imaging information Technologies, Dosti Pinnacle, Unit No, 801, Road No.22, Wagle Industrial Estate MIDC, Thane (W), Mumbai:400 604, India.

² Sun Pharma Advanced Research Company Ltd, Sun Pharma Road, Tandalja, Vadodara-390 020 Gujarat (India).

OBJECTIVE

- Automated analysis and classification of Whole Slide Images (WSI) of Wistar rat thymus and spleen into Normal (N) and Not-Normal (NN) categories based on histological features using algorithms of Digital Image Processing and Deep Learning.
- Establishment of efficacy of the system by comparison with results of pathologists.

INTRODUCTION

- Histopathological examination of animal tissue by pathologists forms a crucial part of preclinical drug toxicology.
- Conventionally pathologists spend valuable time manually scrutinising slides, majority of which are within normal limit.
- This manual method is time consuming, subjective and dependent on the experience and expertise of the reporting pathologist.
- In recent years, Machine Learning techniques have helped in providing increasingly reliable and accurate image analysis solutions in Digital Pathology.
- iADSS combines advanced algorithms of Image Processing with Deep Learning to Analyse and Classify Digital Histopathology Images from preclinical toxicology studies.
- We present results of this system that accurately classifies thymus and spleen digital histopathology images from Wistar rat into "Normal and Not-Normal" categories.

MATERIALS AND METHODS

MATERIALS

Specimen:

- 300 WSI (whole slide images) of Wistar rat thymus and spleen each from control & treated, belonging to preclinical toxicology studies.
- H&E stained slides of both male and female rats belonging to 14, 24 and 36 weeks age groups were used.
- Image Acquisition Device: Leica SCN400 and Nanozoomer XR scanner (40x magnification).
- Image Format: Collection of tiles of fixed dimension (512x512 pixels) at four different magnifications (40X, 10X, 2.5X, and 0.625 X) in the form of a multi-resolution pyramid.

METHODS

a) Training, Testing and Fine-tuning

- Knowledge transfer from pathology domain expert – Normal histological parameters and possible abnormalities (non-proliferative, proliferative and any other lesions).
- Preparation of training data set – Using collection of tiles from 600 images taken at different magnifications (40X, 10X, 2.5X & 0.625X).
- Development of DeepLab model – Segmentation of various tissue parameters using Deep Learning.
- Result refinement – Based on observation of Not-Normal parameters in the segmented regions of capsule, trabeculae, cortex, medulla, red pulp and white pulp across thymus and spleen.

- Trained models of Deep Lab are deployed on the Test data to segment out the tissue parameters.
- Test images are classified as Normal and Not-Normal based on variation in structure and/or statistical properties (shape, size, count etc.) of the detected parameter
- Testing & fine –tuning of models done based on test results & feedback from pathologist

b) Validation

- 100 images from three age groups of Wistar rats randomly selected and classified as Normal and Not-Normal.
- Results validated by internal reviewers and fine-tuned.
- Independent validation on new data-set of 100 images done by external experts.

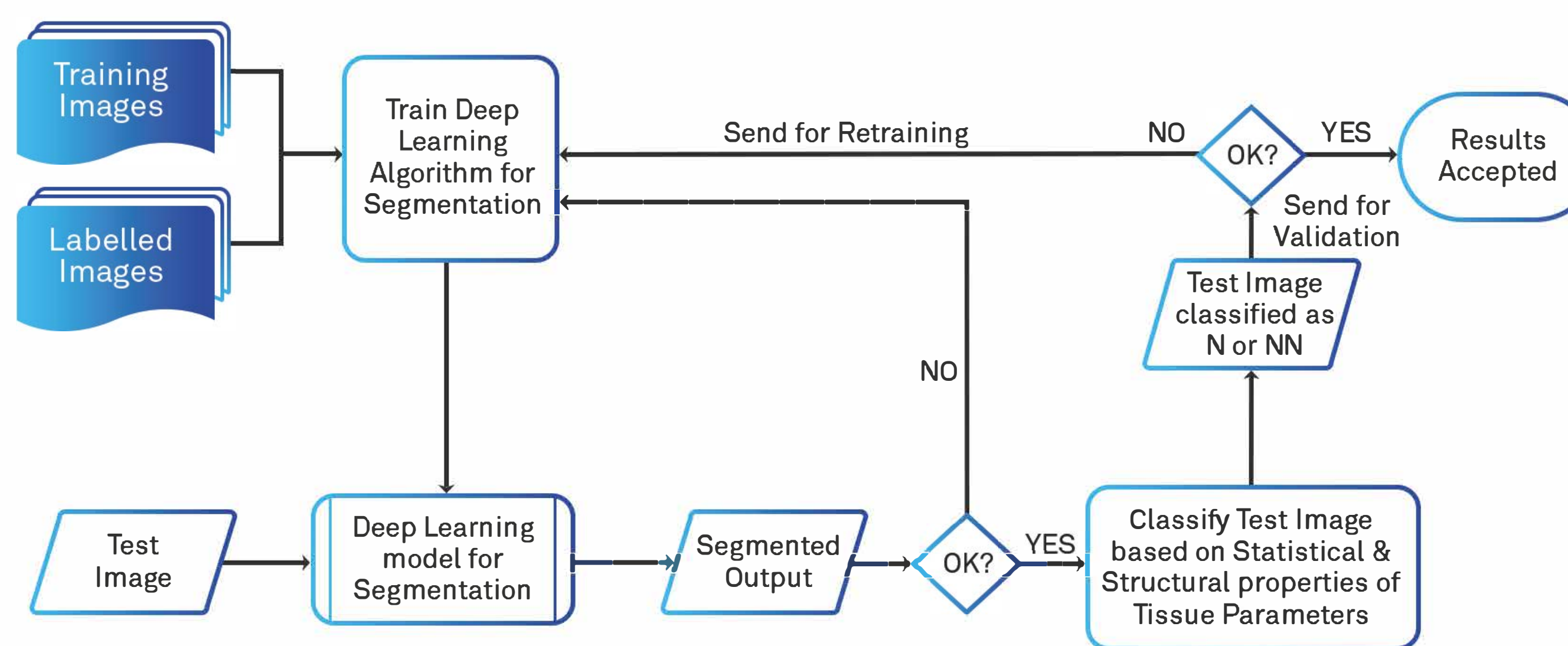
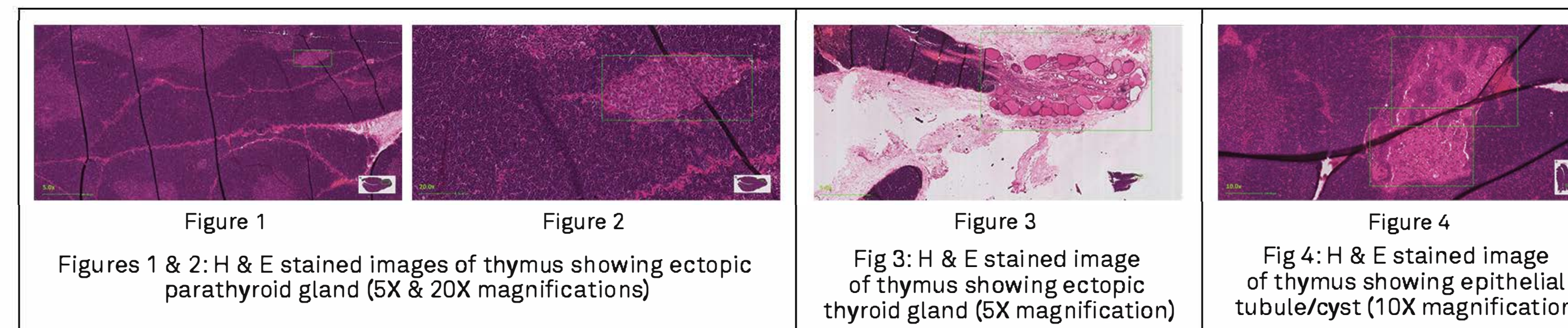
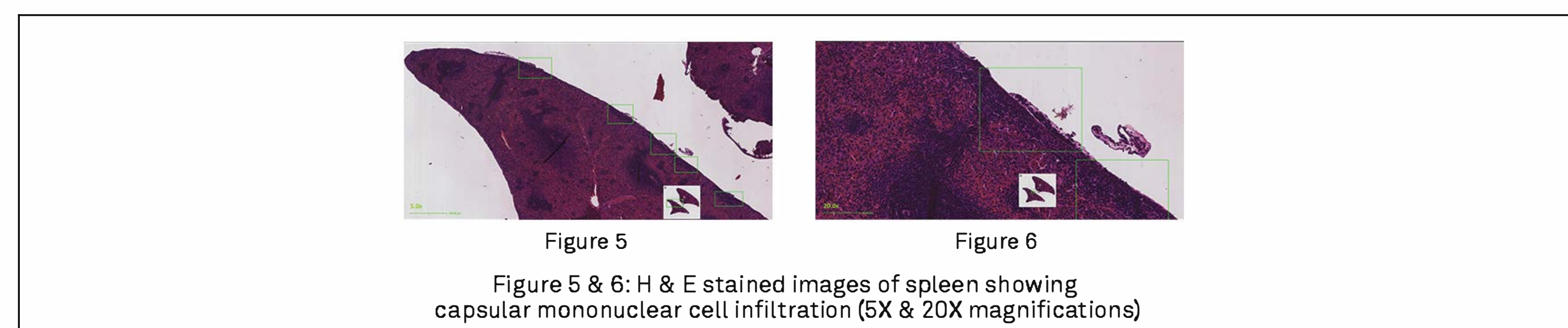


Diagram 1: Process of Flow for Image Classification using Deep Learning

THYMUS



SPLEEN



RESULTS

The normal accuracy (percentage of images correctly classified as "Normal") on automated classification of thymus and spleen images were 100% during the external validation.

| iADSS Results | Pathologist's Results | | Not-Normal Accuracy (PPV)=TP/(TP+FP) | 50 |
|---------------|-----------------------|-------------------------|--------------------------------------|-----|
| | Not-Normal | Normal | | |
| Not-Normal | TP = 20 | FP = 20 | Normal Accuracy (NPV)=TN/(FN+TN) | 100 |
| Normal | FN = 0 | TN = 60 | | |
| | | Sensitivity= TP/(TP+FN) | Specificity= TN/(TN+FP) | |
| | | 100 | 75 | |

Table 1: Validation result of thymus

| iADSS Results | Pathologist's Results | | Not-Normal Accuracy (PPV)=TP/(TP+FP) | 60 |
|---------------|-----------------------|-------------------------|--------------------------------------|-----|
| | Not-Normal | Normal | | |
| Not-Normal | TP = 3 | FP = 2 | Normal Accuracy (NPV)=TN/(FN+TN) | 100 |
| Normal | FN = 0 | TN = 95 | | |
| | | Sensitivity= TP/(TP+FN) | Specificity= TN/(TN+FP) | |
| | | 100 | 97.94 | |

Table 2: Validation result of spleen

(TP: True Positive, TN: True Negative, FP: False Positive, FN: False Negative, PPV: Positive Predictive Value, NPV: Negative Predictive Value)

Accuracy measures for iADSS:

- Normal Accuracy: Percentage of images correctly classified as "Normal"
- Not-Normal Accuracy: Percentage of images correctly classified as "Not Normal"

CONCLUSION/FUTURE DIRECTION

- iADSS produced accurate analysis and classification of thymus and spleen histopathology images of Wistar rat into Normal and Not-Normal categories.
- Results were comparable with Pathologist results
- iADSS can serve as an effective decision support system in preclinical toxicology studies for Wistar rat and thus helpful in expediting drug development process.

References

- Gail Pearse. (2006). Normal Structure, Function, and Histology of the Thymus. Toxicol Pathol 34, 504–514.
- Mark F Cesta. (2006). Normal Structure, Function, and Histology of the Spleen. Toxicol Pathol 34, 455–465.
- Chen, Liang-Chieh & Papandreou, George & Kokkinos, Iasonas & Murphy, Kevin & L. Yuille, Alan, DeepLab: Semantic Image Segmentation with Deep Convolutional Nets, Atrous Convolution, and Fully Connected CRFs, IEEE Transactions on Pattern Analysis and Machine Intelligence (April 1 2018, Volume: 40, Issue: 4, pp: 834 – 848), Epub: 27 April, 2017
- Guo, Y., Liu, Y., Georgioui, T. et al., A review of semantic segmentation using deep neural networks, International Journal of Multimedia Information Retrieval (June 2018, Volume 7, Issue 2, pp 87–93).

Acknowledgement

- Dr. Satish Panchal, DGM – Toxicology (SPARC); Tijo Thomas, DGM – Software Development (AIT)
- Dr. Uttara Joshi, DGM – Business Development (AIT); Umesh Shanghvi, HOD (AIT).